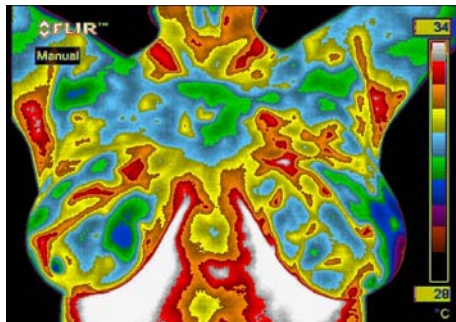
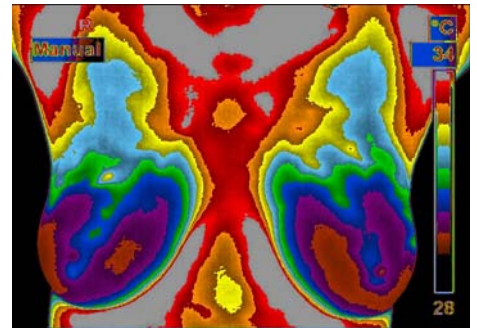



Understanding Your TH Rating

All infrared breast examinations are placed in a specific TH (thermobiological) risk category.

TH 1 – Normal Non-Vascular Image

- Normal thermal presentation.
- When compared to each other, both breasts are even in temperature and cool (dark colors).

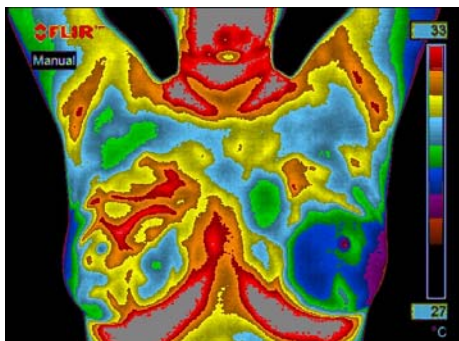
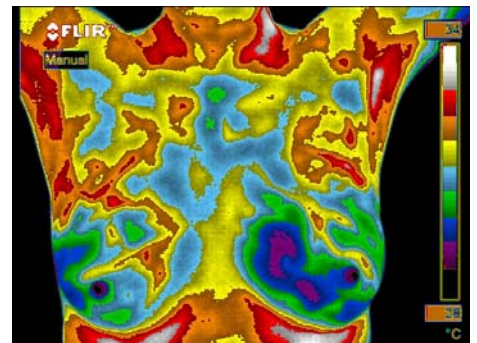


TH 2 – Normal Vascular Image

- Normal thermal presentation.
- Evenly distributed areas of heat (blood vessels) in both breasts.
- If present, specific vascular patterns may indicate hormone influences.

TH 3 – Equivocal Image (questionable)

- Classified between normal and abnormal.
- One breast with one primary or two secondary thermovascular findings.
- Early follow-up infrared examination is indicated to monitor the stability and/or possible progression of any noted regions of interest.
- Follow-up structural imaging is indicated if not recently performed.



TH 4 – Abnormal Image

- Increased risk that an abnormal process may be present.
- Aggressive heating (blood vessels) in one breast vs. the other.
- Early follow-up infrared examination is indicated.
- Follow-up structural imaging is indicated if not recently performed.

TH 5 – Severely Abnormal Image

- Increased risk that an abnormal process may be present.
- Highly aggressive heating (blood vessels) in one breast vs. the other.
- Early follow-up infrared examination is indicated.
- Follow-up structural imaging is indicated if not recently performed.

